



University of Pisa

Department of Oncology, Transplants
and Advanced Technologies in Medicine

Division of Paleopathology

Gino Fornaciari

*Secrets of the Medici Tombs
in Florence*

(A Paleopathologic Investigation)

The American Registry of Pathology
The 15th Robert E. Stowell Lecture
November 9, 2006 – Washington

The Medici were one of the most powerful families of the Italian Renaissance. Starting from the 14th century, their careful management of banking ventures and skilful political actions brought them to the forefront of social and political power in Tuscany and in Florence, the intellectual center of the Western world.



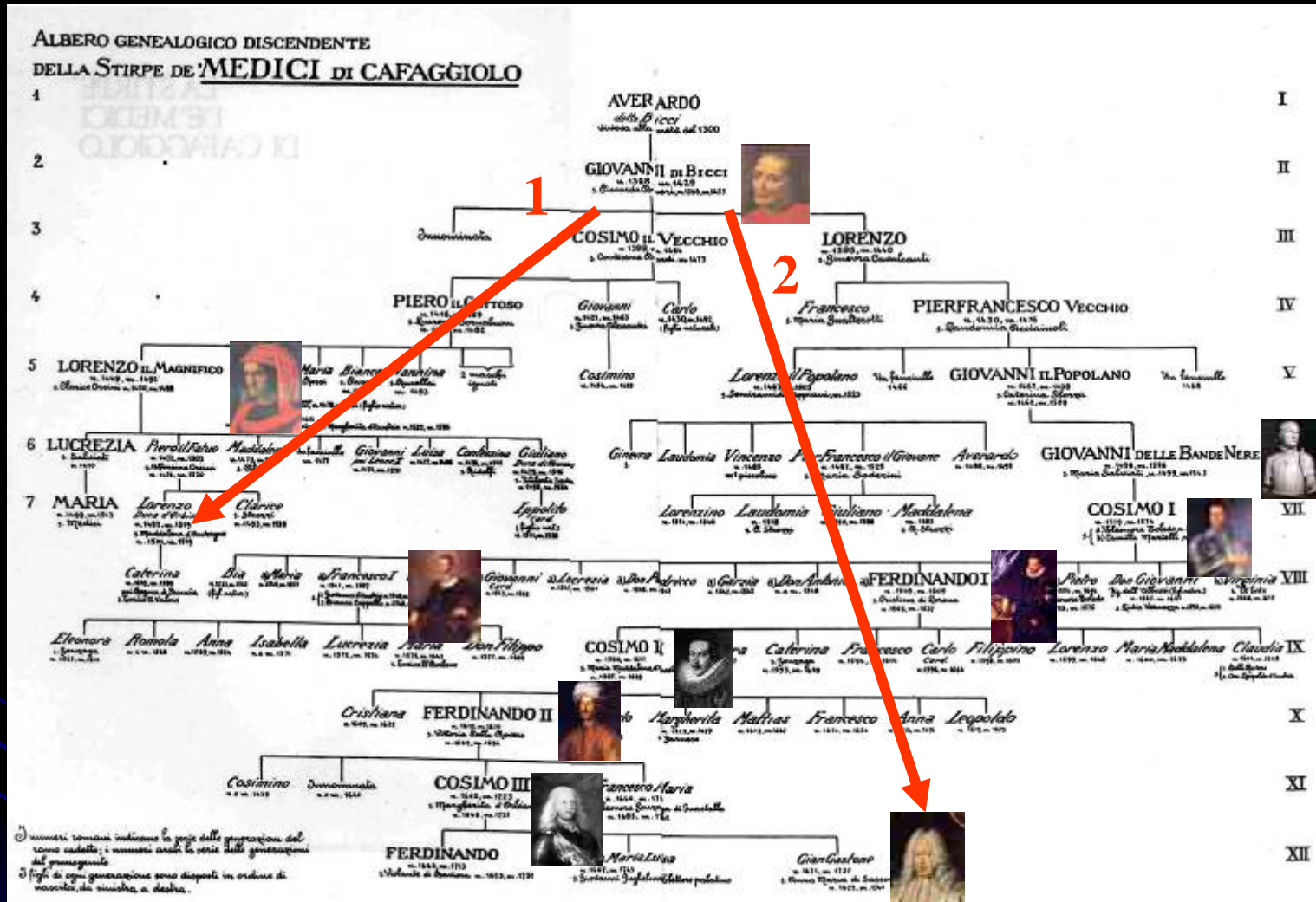
Lorenzo the Magnificent
(1446-1492)
Vasari, Uffizi Gallery

Lovers of art and science, the Medici were patrons of Michelangelo, Leonardo da Vinci, Botticelli, Galileo, and Benvenuto Cellini.



Michelangelo
Tomb of Giuliano de' Medici
(Medici Chapels, Florence)

THE MEDICI FAMILY TREE

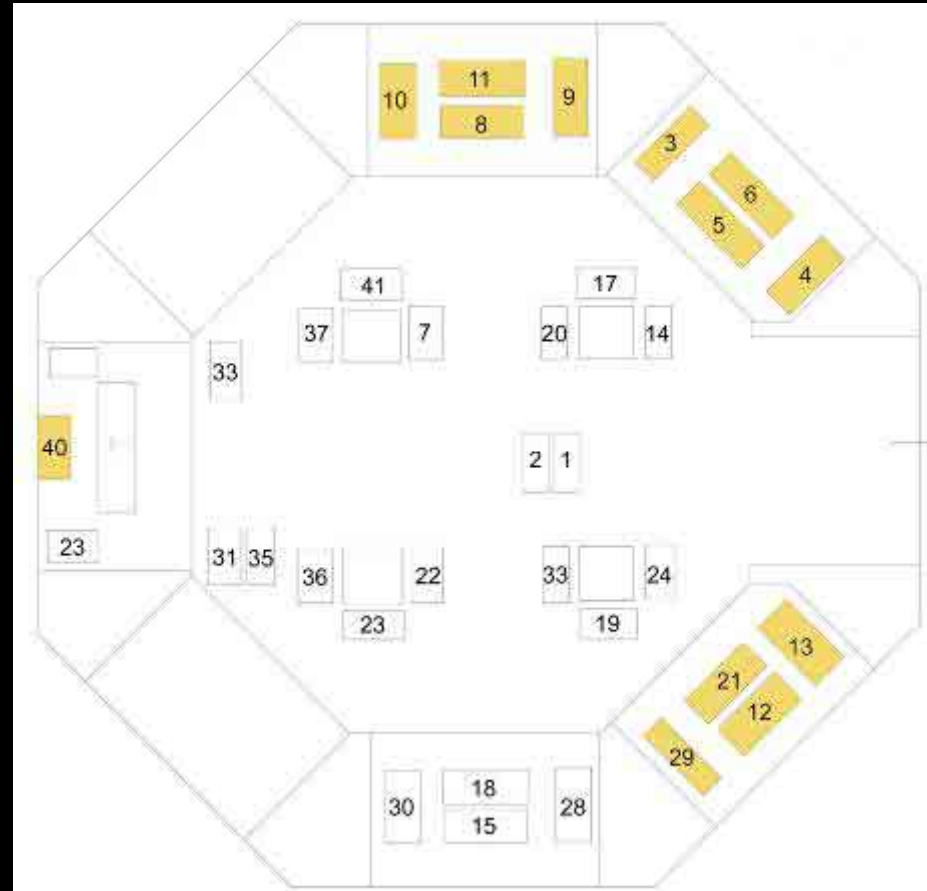


There are two main branches in the Medici family tree: the branch of Lorenzo the Magnificent (1446-1492), and the branch of the Grand Dukes of Tuscany, which began with John of the Black Bands (1498-1526) and ended with Gian Gastone (1671-1737), the last Grand Duke. The most important members of this impressive dynasty were buried under the vaults of the Basilica of San Lorenzo in Florence.

THE CRYPT OF SAN LORENZO



The crypt of the Basilica of San Lorenzo in Florence, Mausoleum of the Grand Dukes of the Medici family.



Map of the crypt, with the Medici tombs already explored in yellow.

THE "RICH" PATHOLOGY OF THE MEDICI FAMILY

(from archive documents)

INFECTIOUS AND PARASITIC DISEASES

METABOLIC DISEASES

JOINT DISEASES

CARDIOVASCULAR DISEASES

POISONINGS

TUMORS

MALFORMATIONS

smallpox
tuberculosis
malaria
syphilis

obesity
anemia
urinary stones

familial
arthritis

arteriosclerosis

chronic
intoxications

breast cancer

dwarfism



Ferdinando II (1610-1670)



Eleonora from Toledo (1522-1562)



Francesco Maria (1660-1710)



Maria Salviati (1499-1543)



Ferdinando (1663-1713)



Cosimo III (1642-1723)



Cosimo I (1519-1574)



Francesco I (1541-1587)



Anna Maria Luisa (1667-1743)



Maria Cristiana (1609-1632)

THE “MEDICI PROJECT”



John of the Black Bands
(1498-1526)



Cosimo I
(1519-1574)

In 2002, dr. Antonio Paolucci, Superintendent of Florentine Museums, granted permission to examine 49 of the Medici burials in the Basilica. The "Medici Project" focuses on the Grand Dukes, who are less known than Lorenzo and his descendants.

The project involves collaboration among the University of Pisa, the University of Florence, and the Superintendence of Florentine Museums.

The research programme includes funerary archeology, physical anthropology, paleonutrition, parasitology, pathology, histology, histochemistry, immuno-histochemistry, electron microscopy, molecular biology, and identification of ancient pathogens.

The most recent biomedical techniques are employed in order to obtain as much information as possible about the life style, the health and the environment of these famous rulers of Renaissance Florence.



Eleonora from Toledo
(1522-1562)



Anna Maria Luisa
(1667-1743)

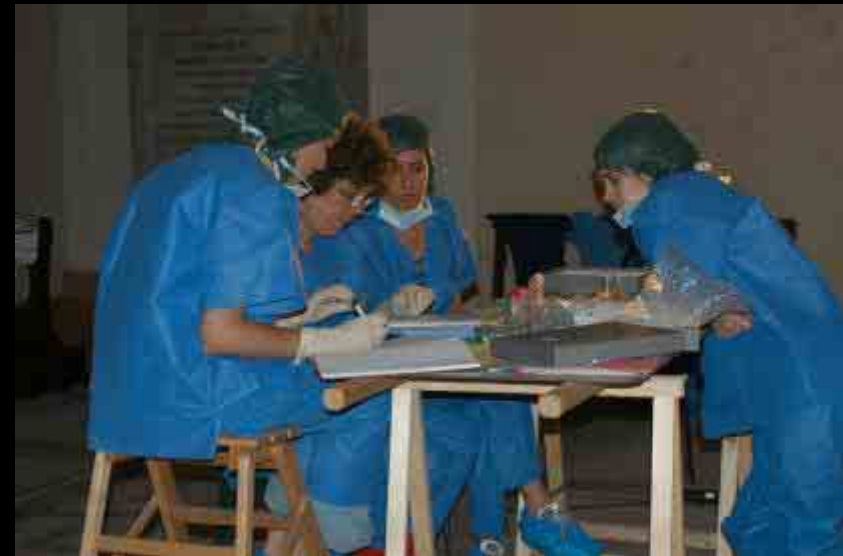

Lorena Chapel

In order to conduct this study, we set up a temporary laboratory in the Lorena Chapel, the funerary crypt of the Grand Dukes of the Lorena dynasty, which ruled Florence and Tuscany after the Medici until 1859.



Temporary laboratory

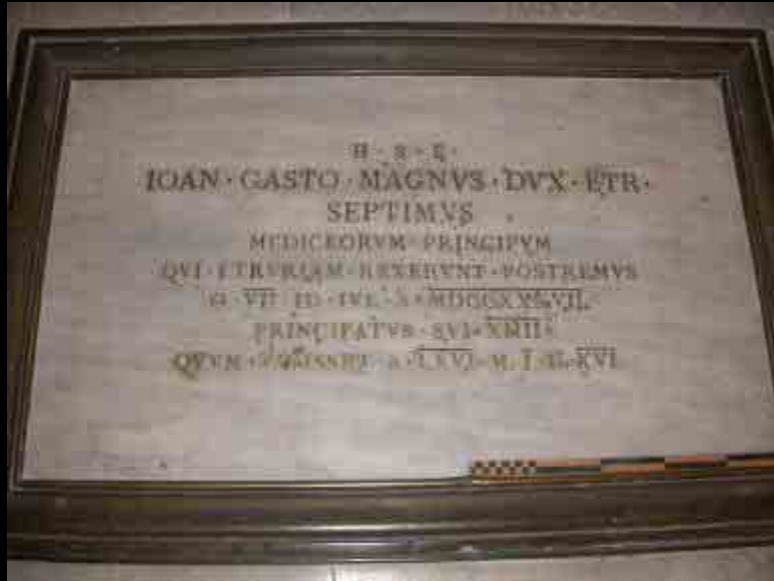

Some anthropologists at work



Richter (1737), Florence, Palatina Gallery

We decided to begin our examination with the intact tomb of Gian Gastone (1671-1737), the last Grand Duke of the Medici.



This is the slab of marble with his epigraph...



...and this is the position of a plain dark marble disk with no epigraph, considered a simple floor decoration.

The removal of the marble disk in the floor of the chapel displayed a secret opening with a small stone stair leading to a hidden crypt.



GEOGRAPHICA

I POPOLI, I LUOGHI E LA NATURA DEL NOSTRO UNIVERSO

VERBA I segreti dei Medici

I corpi riesumati raccontano la storia del casato


La potente pancia che spillava da secoli un avvelenamento sulle Cappelle Medicee di Firenze viene trascinato di peso. Sublime come un'opera d'arte, il professor fuoriesce dalla lastra di marmo. Una raffinata curatela è immediatamente settimano che, una volta illuminato, rivela il suo oroscopo: un uomo, un'età quella con i tratti di Gianmario, ultimo granduca della famiglia dei Medici. Dal 1500 al 1700, un

di archeologia e antropologia del "Progetto Medici", guidato da Gino Fornaciari, direttore del laboratorio di Paleopatologia dell'Università di Pisa (nella foto: il professor Medici) e da Donatella Lippi, storica della medicina, sta riesumando i corpi di alcuni membri dell'illustre casato rinascimentale (che morì in Toscana fino al 1713), perché il giurista Giugliano non sono stati. Come veri e propri medici, i

NATIONAL GEOGRAPHIC • MAGGIO 2013

The hidden crypt at the moment of discovery.

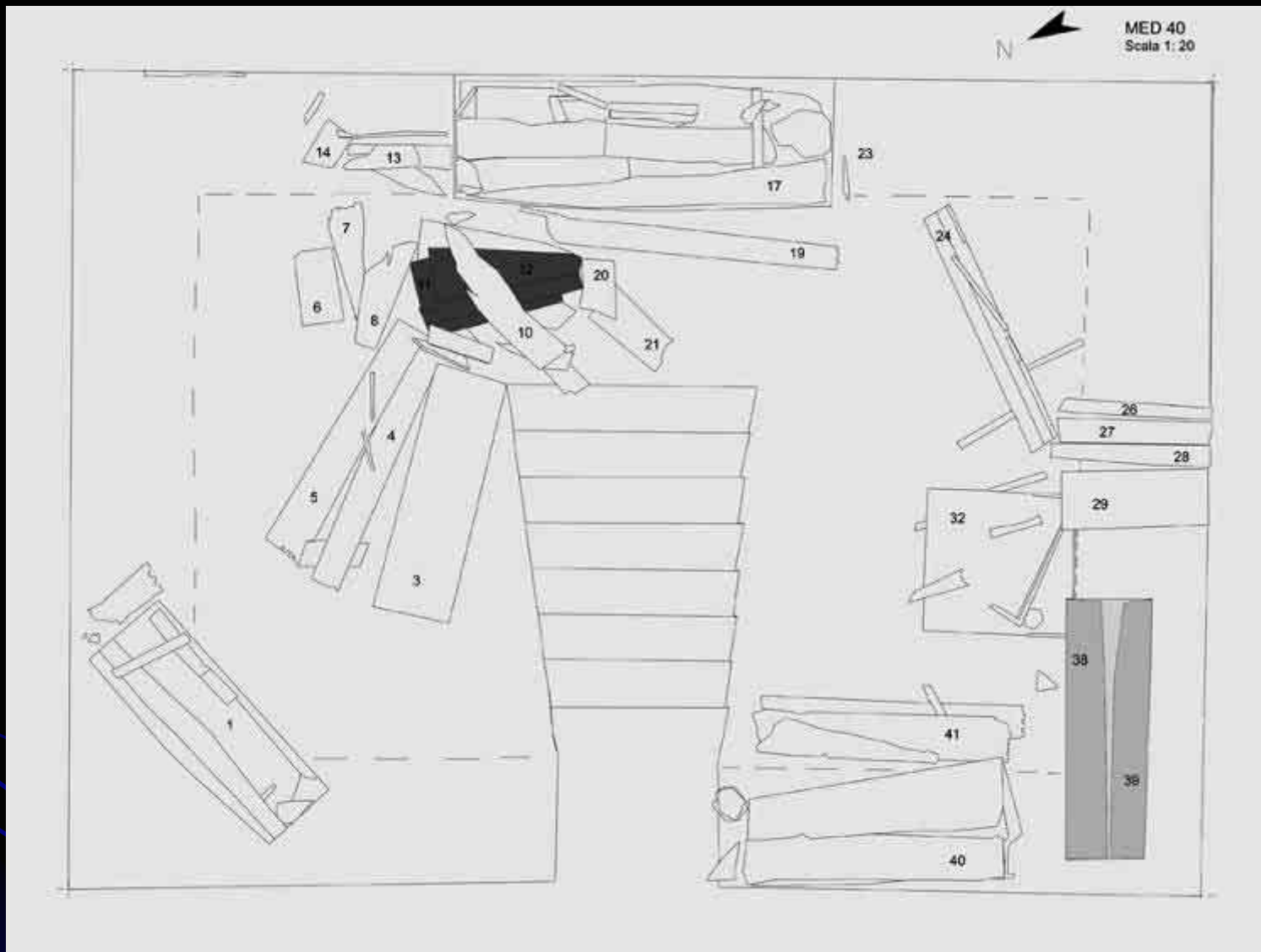
(by NATIONAL GEOGRAPHIC)



An image of the Florence
flood of 1966
(by NATIONAL GEOGRAPHIC)




A low raised platform running around the base of the crypt's walls supported a large sarcophagus and many small wooden coffins; these coffins had completely collapsed on the floor, covered by a layer of dry mould from the disastrous flood of 1966.



The archeological relief, with the exact position of the great sarcophagus of Gian Gastone opposite the stairs and many small coffins collapsed on the floor or variously distributed on the plane.

A special climate-control chamber was constructed over the entrance of the crypt, to cope with the extreme dampness (90%) and high temperature (30°C) and to avoid additional damage to the coffins and bodies by the introduction of external air during the archaeologists' examination.



The outer wooden sarcophagus of the Grand Duke Gian Gastone, apparently well preserved, was in fact very fragile, because of the high level of humidity.



The lid of the sarcophagus, badly damaged, had collapsed into the interior...

...revealing the inner coffin of lead, with a large Christian cross and six iron handles on the lid.



The body of the Grand Duke was intact: he was covered by the silk Great Cape (*Cappa Magna*) of the Grand Master of Knights of the Order of St Stephen and was still wearing his funerary crown.





The impressive vision of the skull of Gian Gastone with his funerary crown, in gold-plated copper.



He bore a silver crucifix (red arrow) on his chest and a large lead tube (yellow arrow), probably containing a parchment document celebrating his life.



On either side of the Grand Duke's head were two large golden medallions (green arrow)...



...masterpieces of the royal engraver Louis Siries (1686-1757).

The obverse design shows a bust of the Grand Duke on top of a monument between two mountains. Beneath the monument, the figure of *Securitas* (Security) appears with two *genii* who are rejoicing in front of her.

The Latin inscription reads "*IO(HANNIS) GASTO(NIS) I ETR(URIAE) MAG(NUS) DUX VII*" (Gian Gastone I, VII Grand Duke of Tuscany).



Luigi Series (1737)

The design on the reverse shows a ruined Temple, with seated figures representing the Arts mourning the death of the Grand Duke, with the Latin inscription "*AMPLIATORI ARTIUM*" (to the Patron of Arts).



Luigi Series (1737)



Other small coffins of children, collapsed on the floor or variously distributed on the raised floor level, were visible in the crypt.





Contrary to all expectations, several of the burials in the small wooden coffins were fairly intact. The elaborate costume of a 5-year-old child, complete with shoes and silver crown, showed an excellent state of preservation.



The red silk jacket with a thin collar and buttons was adorned with silver gallons and large plus-fours in the same flowery fabric.



Bizzelli (1586), *Giovanna from Austria and her son Filippo*, Florence, Uffizi Gallery



Alessandro Allori (1581?)
Madrid, Prado Museum

The costume is very similar to that worn by Don Filippino (1577-1582), a young son of the Grand Duke Francesco I, portrayed with his mother, the Grand Duchess Giovanna from Austria.



Baroccio, Florence, Palatina Gallery

Other burials as, for example, the one of a baby of about 9 months, dressed in a precious silk vest with silver cuffs, resulted less well preserved.



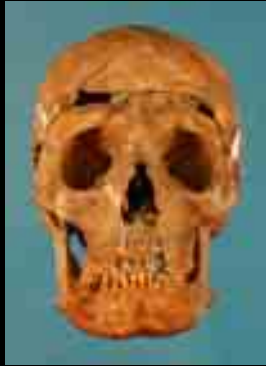First results





Bronzino (c.1543), Florence, Uffizi Gallery

Cosimo I (1519-1574)



Anthropology

The study of the skeleton of Cosimo I (1519-1574), first Grand Duke of Tuscany, revealed a vigorous man with a skeletal age of 50-60 years and a stature of 1.78 m.

His well-developed muscular insertions confirm the historic descriptions of his great physical strength and robusticity.

Skeletal markers of habitual horseback riding are all present, consistent with his reputation of a fine, skilled horseman.



Giambologna (1598), Florence, Piazza della Signoria

“Clinical history”

Cosimo I survived several illnesses, including smallpox, malarial fevers at ages 24 and 25, 'gravel' (renal or bladder *calculi*) at ages 41-43, and bronchitis.

Contemporary descriptions indicate that he also experienced severe early arteriosclerosis with **paralysis** (of the left arm at the age of 48, right hemi-paresis, dyslalia, psychological instability, urinary incontinence, and aphasia and agraphia at the age of 54).

He also suffered from an acute articular disorder of the right knee, termed 'gout' by the court physicians, at the ages of 49 and 52-53. Finally, death was caused by 'catarrhal fever', probably bronchopneumonia, at the age of 55.



Vasari (1565), Florence, Palazzo Vecchio

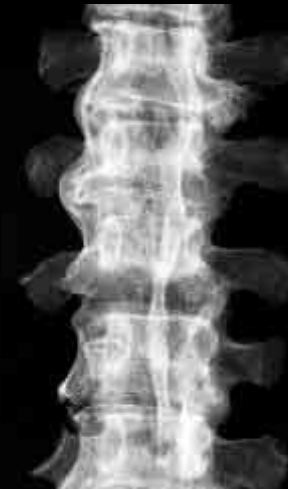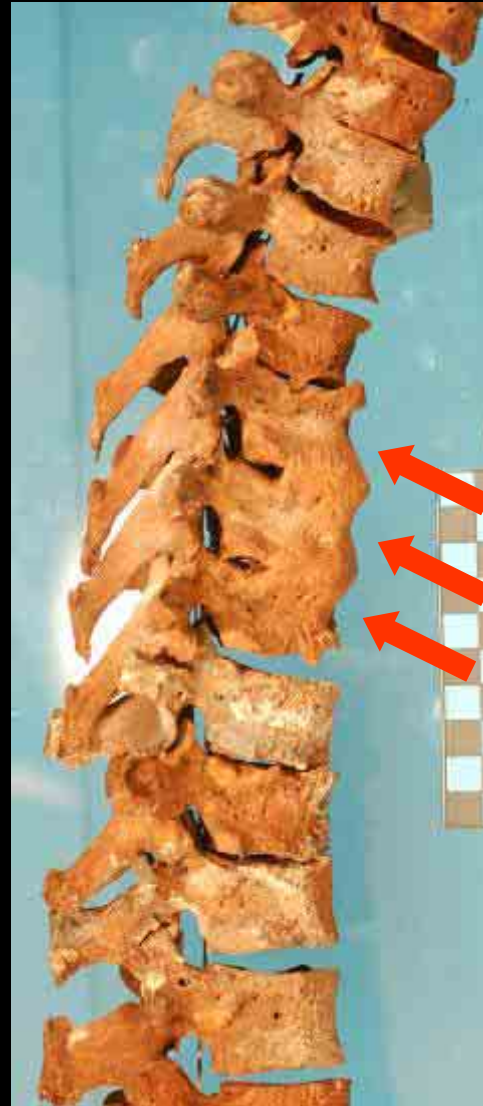
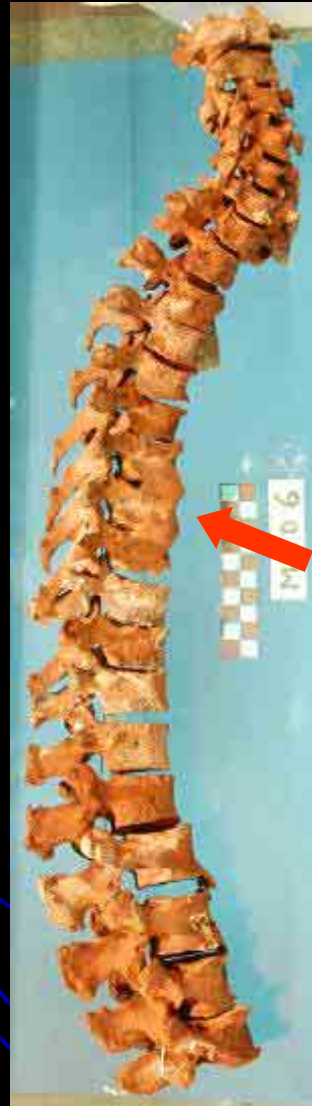Paleopathology

The paleopathological study of the skeleton revealed that Cosimo I suffered from diffused arthritis in his lower thoracic/lumbar spine, sternum, shoulders, elbows, hips, knees and ankles, probably caused by his vigorous physical activities.



Poggini (1557), Prato, city hall.

Ossification of the anterior right vertebral ligament at the level of the 6th, 7th and 8th thoracic vertebral bodies and the diffused ossifications of the articular ligaments demonstrate that he was affected by DISH (Diffuse Idiopathic Skeletal Hyperostosis), an articular disease linked to diabetes and obesity.

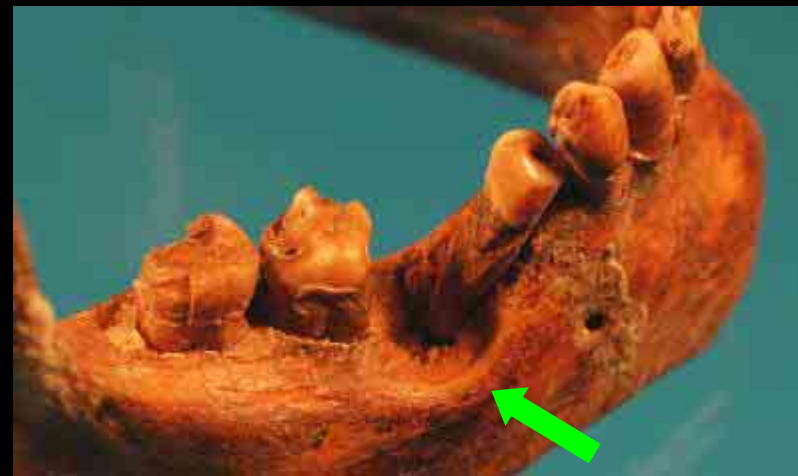
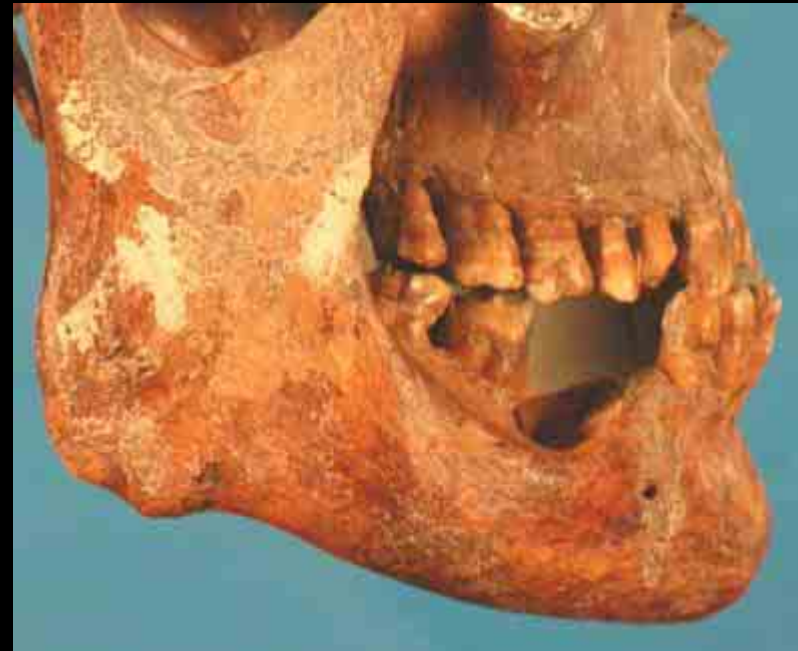
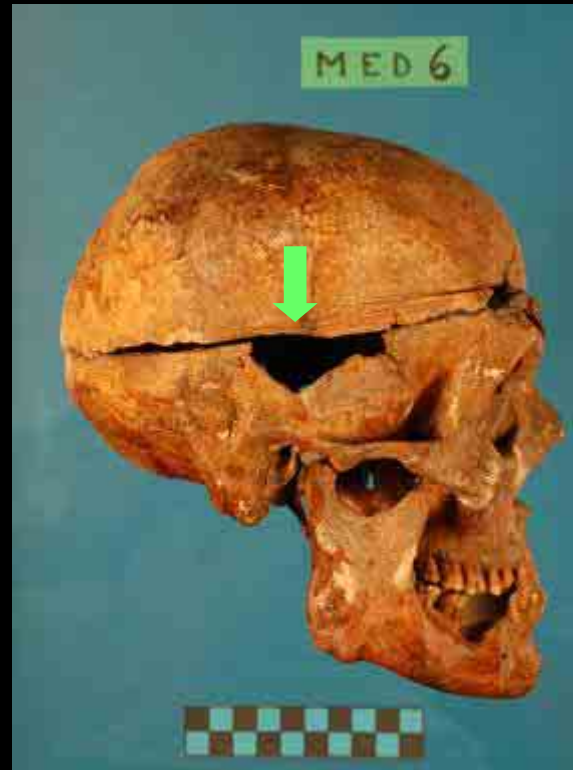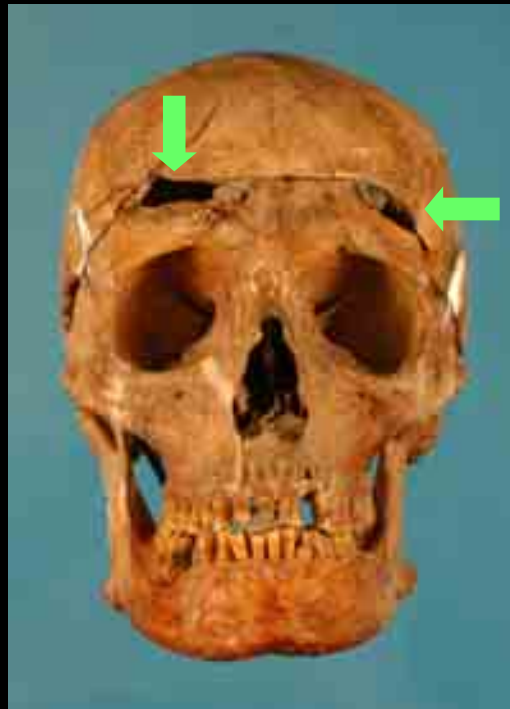
X-ray Prof. N. Villari
(University of Florence)

The ossification of the anterior right vertebral ligament, at the level of the thoracic vertebral bodies (red arrows), is typical of DISH.

Dental Pathology

The teeth show a severe periodontal disease, with a large abscessual cavity and *ante mortem* loss of the first inferior right molar (green arrow).





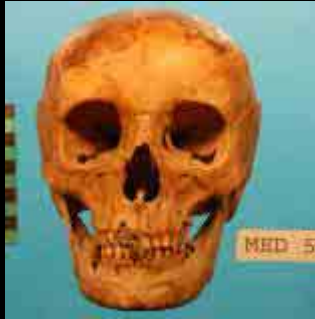Autopsy

At autopsy of the Grand Duke's body, the court surgeon tried twice but with no success to cut open the skull at the level of the right parietal bone; only at the third attempt was he able to make a rough horizontal cut. The surgeon then opened the skull by inserting a large chisel into the cut, which damaged the skullcap in three different points (green arrows).



Bronzino (c.1545), *Eleonora from Toledo with her son*,
Florence, Uffizi Gallery

Eleonora from Toledo (1522-1562)



Anthropology

The study of the skeleton of Eleonora from Toledo (1522-1562) indicated a woman aged 36-46 years, 1.58 m tall.

Her muscular insertions at the forearm, thorax, thigh, and leg indicate a considerable physical activity.



Bronzino (1543), Prague, Národní Galerie

“Clinical history”

The “clinical history” of Eleonora is dominated by the high number of deliveries: between the ages of 18 and 32, she gave birth to as many as 11 babies!

Probably for this reason, around the age of 29 she developed pulmonary tuberculosis which, together with an attack of pernicious malaria, killed her at the age of 40.


Her famous portrait in later life by Bronzino shows a very thin and ailing Eleonora, affected by phthisis.



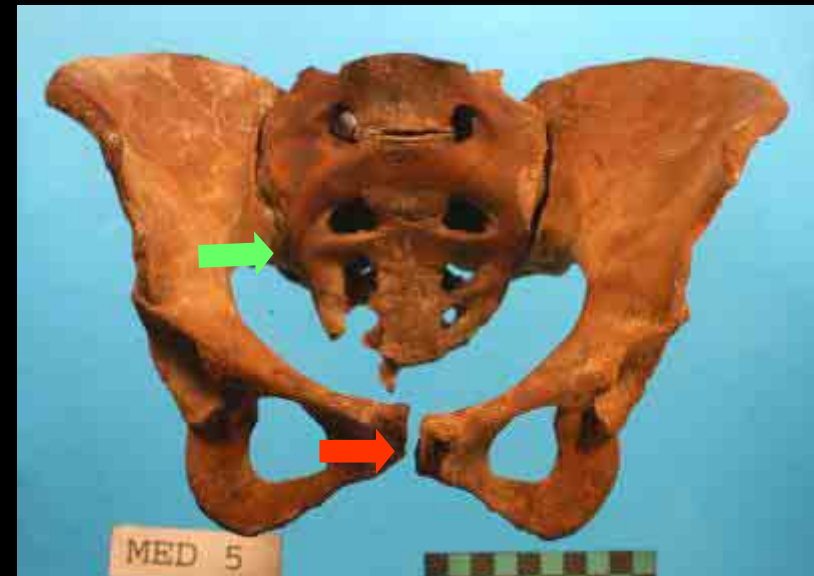Bronzino copy (1558), *Eleonora suffering from tuberculosis*, Assisi, private collection.

Paleopathology

The paleopathological study of Eleonora's skeleton revealed that she experienced a mild form of rickets during childhood, evident from the curvature of her tibias. In other words, she would have appeared a bit "bow-legged".

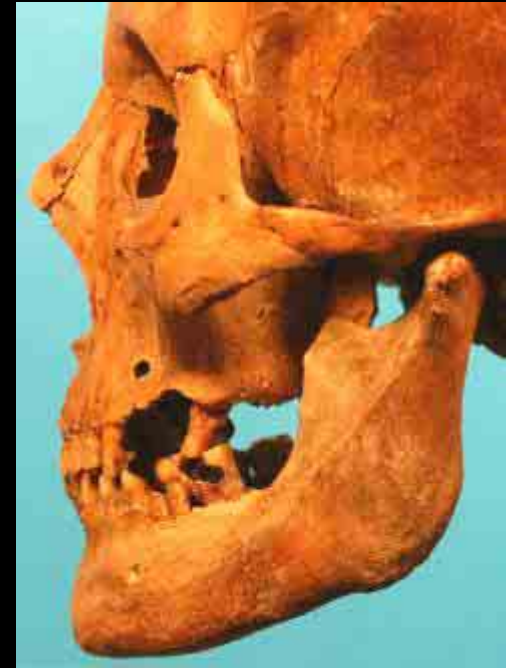

Not surprisingly, she presents pelvic skeletal markers associated with multiple deliveries, as large pre-auricular grooves (green arrow) and retropubic *foveae* (red arrow).

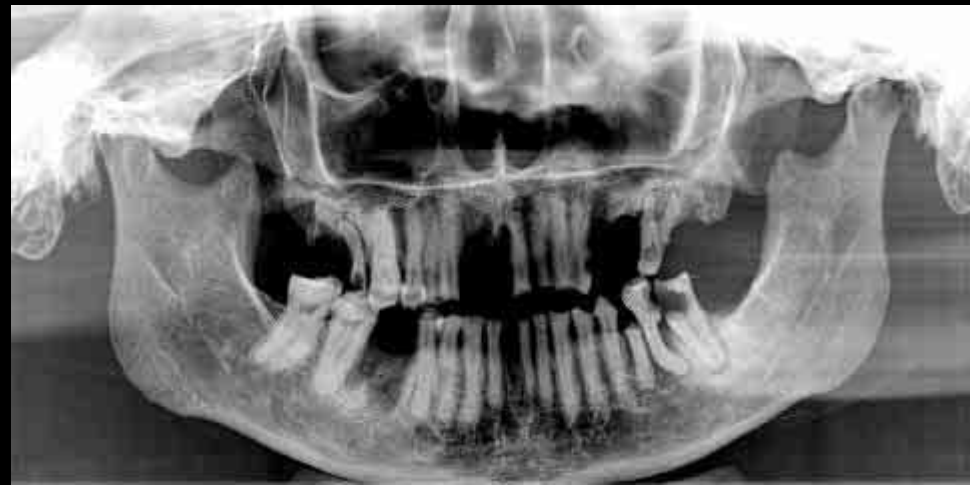

At the time of death, Eleonora suffered from severe dental disease with destructive caries, probably a consequence of the depletion of calcium caused by her many pregnancies.

She also displayed diffused, slight arthritis (in lower spine and shoulders, elbows, hips, knees, and ankles).



Allori (c.1572), Florence, Palazzo Vecchio

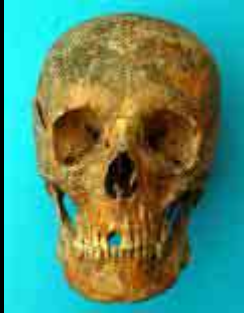

X-ray Prof. N. Villari
(University of Florence)



Allori? (c.1567), Florence, Uffizi Gallery

**Francesco I
(1541-1587)**



Anthropology

The third burial examined was that of Francesco I (1541-1587) second Grand Duke of Tuscany, a robust man with a skeletal age of 40-50 years and a stature of 1.74 m.

The muscular insertions indicate a man of great physical strength. The skeletal markers associated with habitual horseback riding, already noticed for Cosimo I, are almost all present.

This new data changes completely the traditional view of Francesco I as an intellectual, sedentary scholar, nicknamed "the prince of the *studiolo*" for his devotion to humanistic and alchemic studies. On the contrary, Francesco led a physically active life.



Rubens, Paris, Musée du Louvre

“Clinical history”

The “clinical history” of Francesco I is well known from archival records.

After surviving several episodes of non-severe illnesses (such as acute bronchitis at the age of 20 and bronchopneumonia at the age of 38), after 35 he grew rather fat, suffered from 'gravel' with colic at 44 and 45 years of age, and died of pernicious malaria at 46.



Stradano (1570), Francesco I “alchemist”,
Florence, Palazzo Vecchio.

The Grand Duke was very fond of alchemic studies, which he practiced with great success. He was able to fuse rock crystal and to produce, in his laboratory in the Pitti Palace, a type of expensive ceramic ware called "Medicean porcelain", very similar to luxury wares imported from China.

As an alchemist, he was certainly exposed to chronic metallic poisons, and the toxicological study of his bone tissue will be of great importance in establishing the exact degree of his exposure to different substances.

Paleopathology

The paleopathological study of the skeleton showed that Francesco I suffered from moderate vertebral and extra-vertebral arthritis.



Pulzone (c.1580), Florence, Palatina Gallery

Finally, the sectioning of the body of the sternum (red arrow), clearly made in the course of autopsy of Francesco's body, is worth mentioning.



Allori (1570), Florence, Argenti Museum

**Giovanna from Austria
(1548-1578)**



The reputation of Giovanna as a very religious woman was confirmed by the discovery of her well preserved rosary, made of simple wood.

“Clinical history”

Giovanna appears in numerous portraits; she was not very attractive, some contemporary reports even describe her as "hunchbacked". She survived six very difficult deliveries, but died at the age of 30 during childbirth after the rupture of the uterus.



Bizzelli (1586), *Giovanna from Austria and her son Filippo*, Florence, Uffizi Gallery

Anthropology

Study of the skeleton of Giovanna from Austria reveals that she was a woman with a skeletal age of 25-35 years and stature of 1.58 m. The weak muscular insertions suggest very limited physical activity.

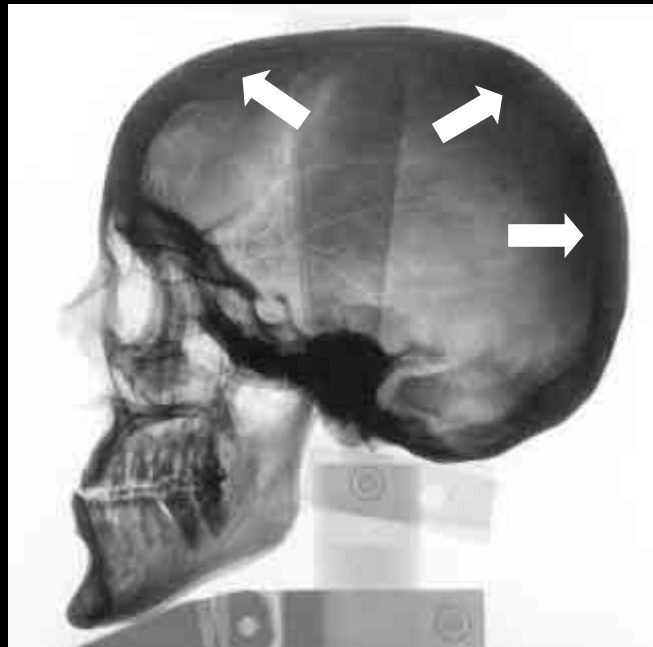
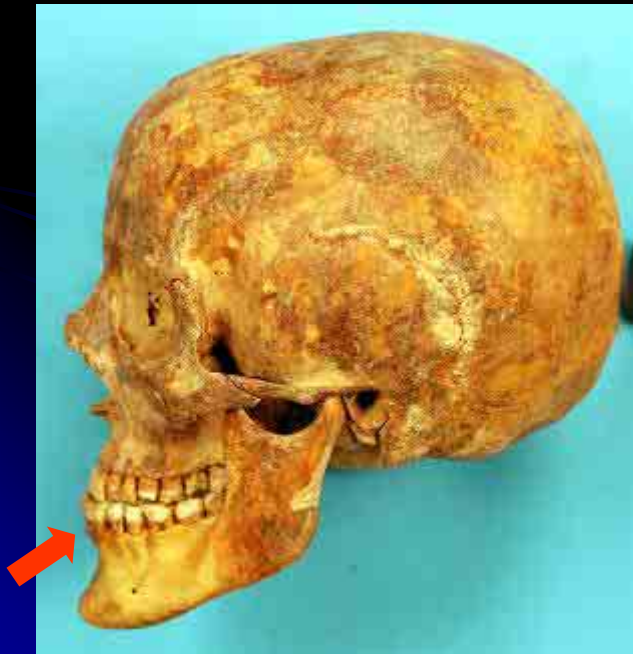
Her sternum had been sectioned in the course of the autopsy (red arrows).



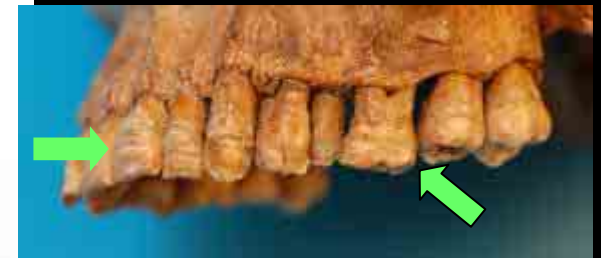Paleopathology

The paleopathological study of the skeleton reveals a veritable collection of disorders:

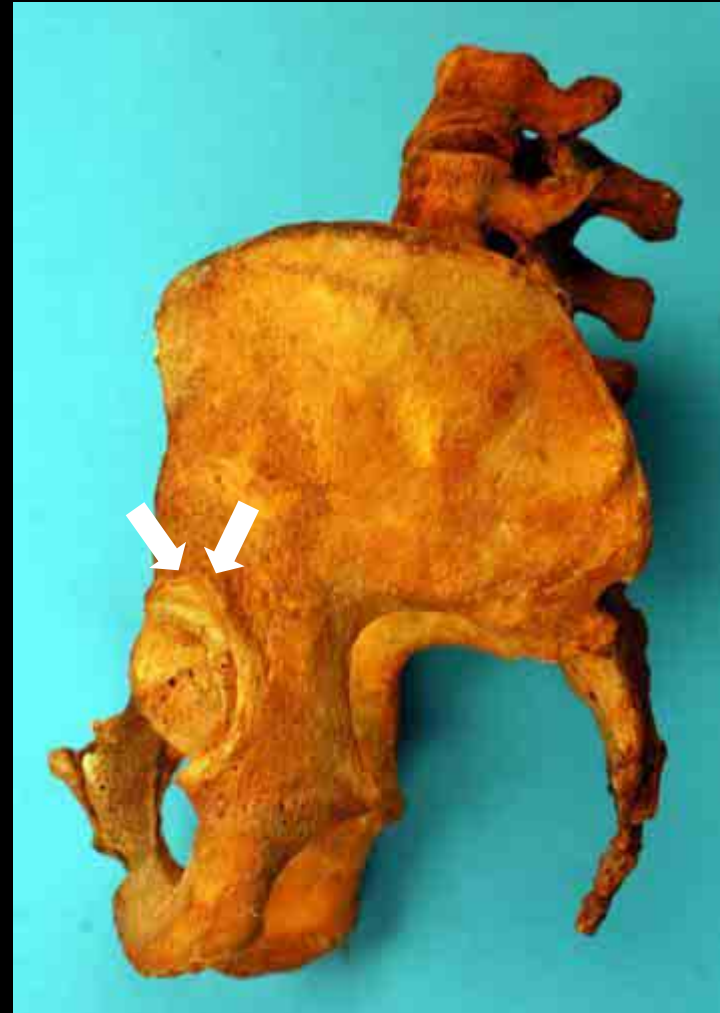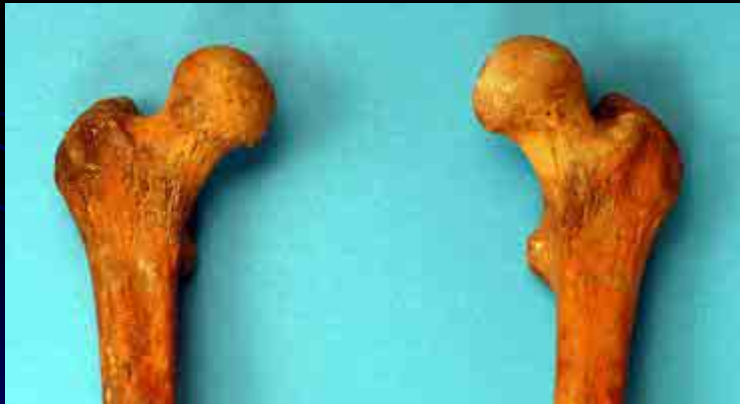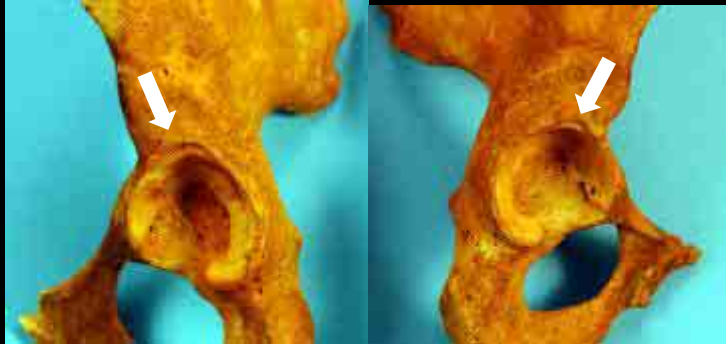
- mandible prognatism – the famous Habsburg jaw! – (red arrow)
- marked congenital hyperostosis (ca 1 cm) of the cranial vault (white arrows)
- *amelogenesis imperfecta* of the dental crowns (green arrows)



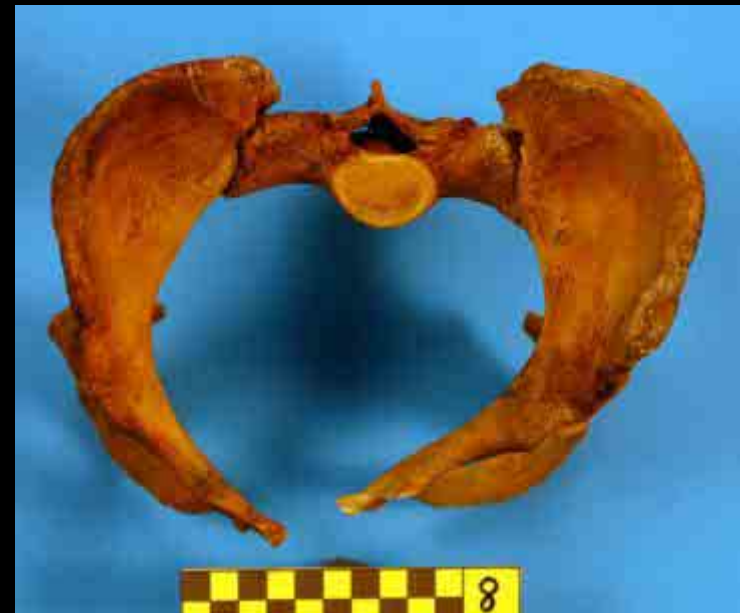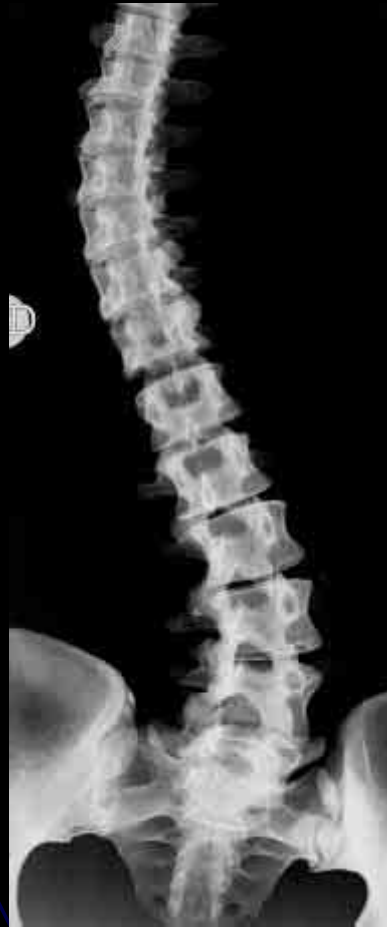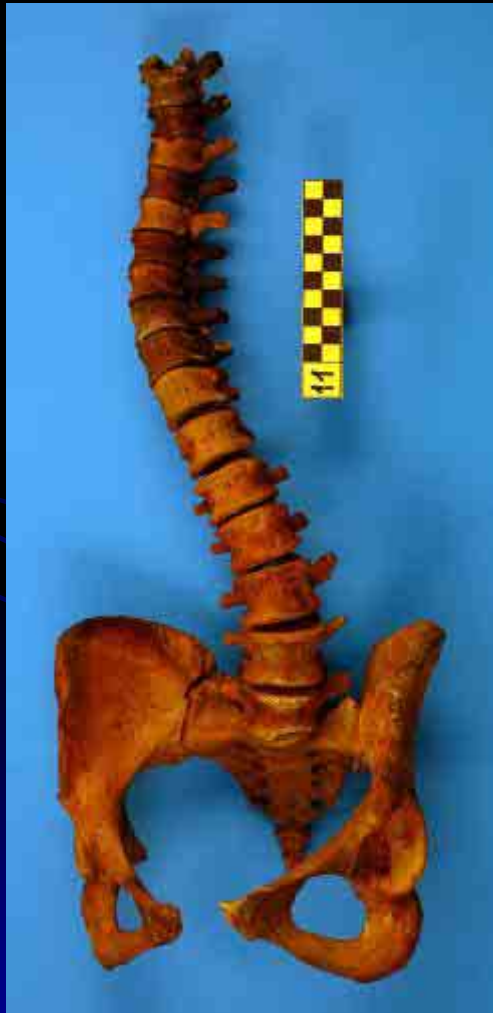X-ray Prof. N. Villari
(University of Florence)



- incomplete congenital dislocation of the hip (white arrows)

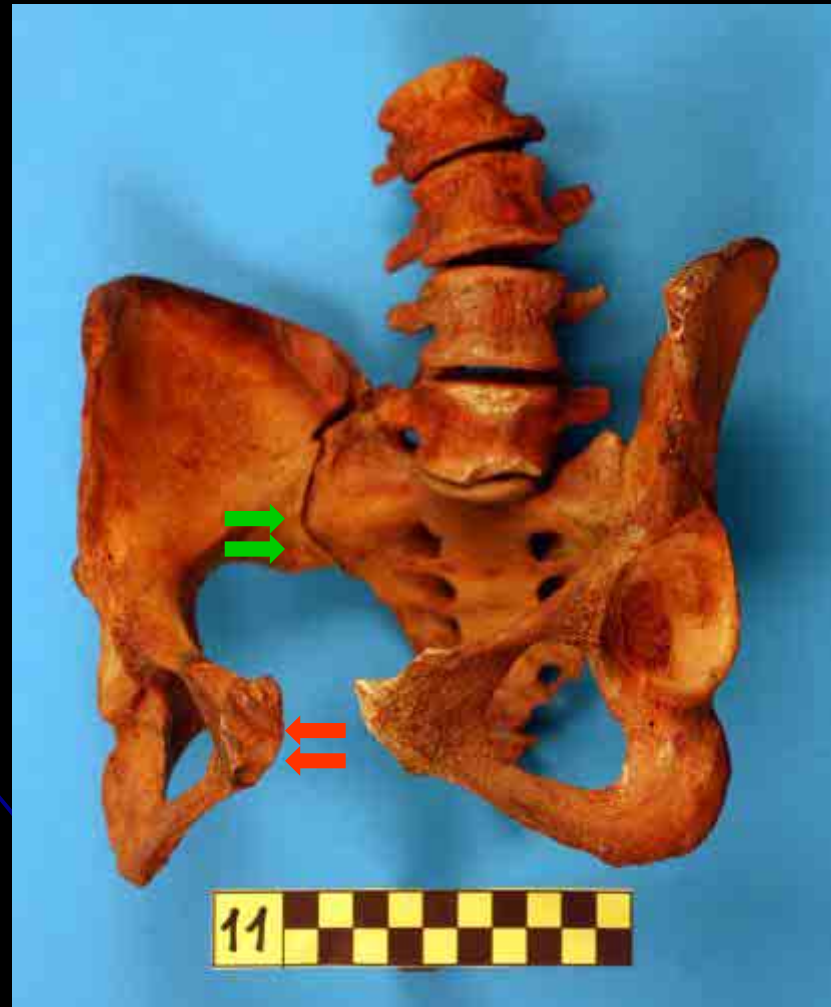


- severe scoliosis of the lumbar column with impressive deformity of the pelvis (which well explains her difficult deliveries and death for the ruptured uterus)



X-ray Prof. N. Villari
(University of Florence)

The enormous retro-pubic *foveae* in her pubic symphysis (red arrows) and the deep pre-auricular *sulci* (green arrows) bear witness to her numerous difficult deliveries.





Pulzone (c.1582), Florence, Uffizi Gallery

Ferdinando I (1549-1609)

Anthropology

The skeleton of Ferdinand I (1549-1609), 4th Grand Duke of Tuscany, reveals a vigorous man with skeletal age of 55-65 years and stature of 1.73 m.

The muscular insertions are those of a very strong man.

The skeletal markers associated with habitual horseback riding are almost all present, consistent with his reputation of a fine horseman.



Giambologna, Vienna, Liechtenstein Princes Collection

“Clinical history”

Ferdinand I survived several illnesses, including a severe episode of pernicious malaria at the age of 14, and some bronchites; after the age of 41 he grew rather fat.

From the age of 33 until death, he suffered from many acute attacks of gout, generally of the left foot, typically positioned in the *hallux*.

Finally, death was caused by heart failure with dropsy and intestinal obstruction at the age of 60.

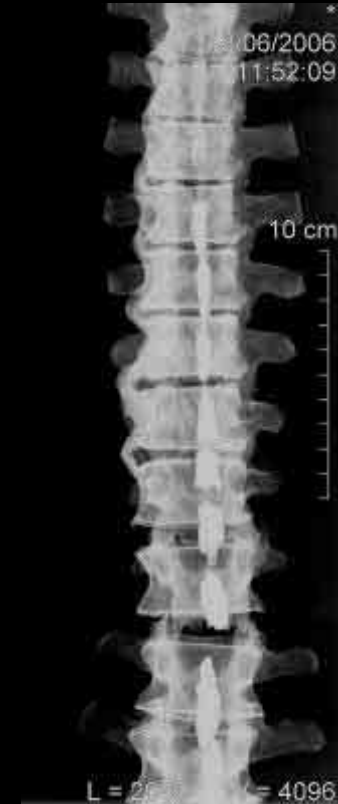
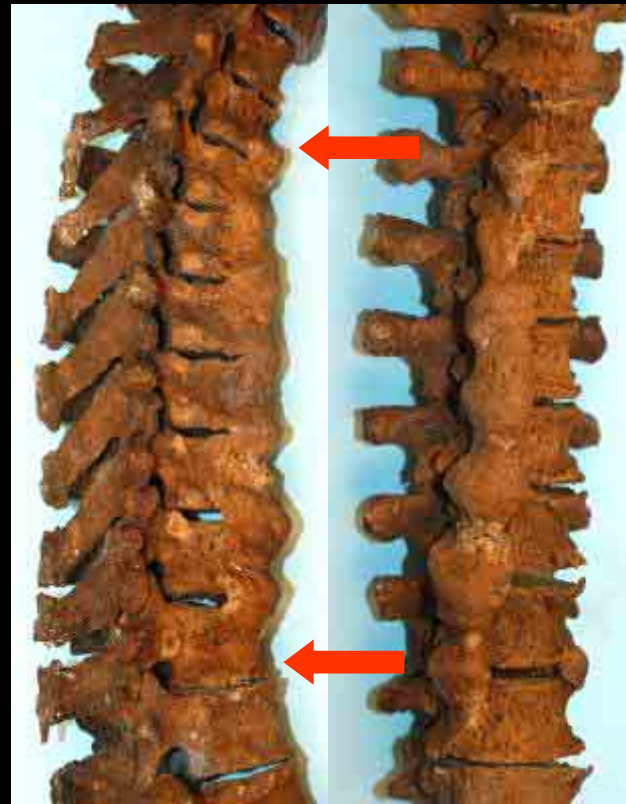
Tiberio Titi? (1605-1609), Pisa, S. Matteo Museum

Paleopathology

The paleopathological study of the skeleton reveals that Ferdinand I suffered from diffused arthritis (of the spine, sternum, hips, knees and ankles), probably due to his strong physical activity.

Ossification of the anterior right vertebral ligament at the level of the 5th-11th thoracic vertebral bodies (red arrows) and the diffused ossifications of the ligaments demonstrate that Ferdinand, like his father Cosimo, was affected by DISH (Diffuse Idiopathic Skeletal Hyperostosis).

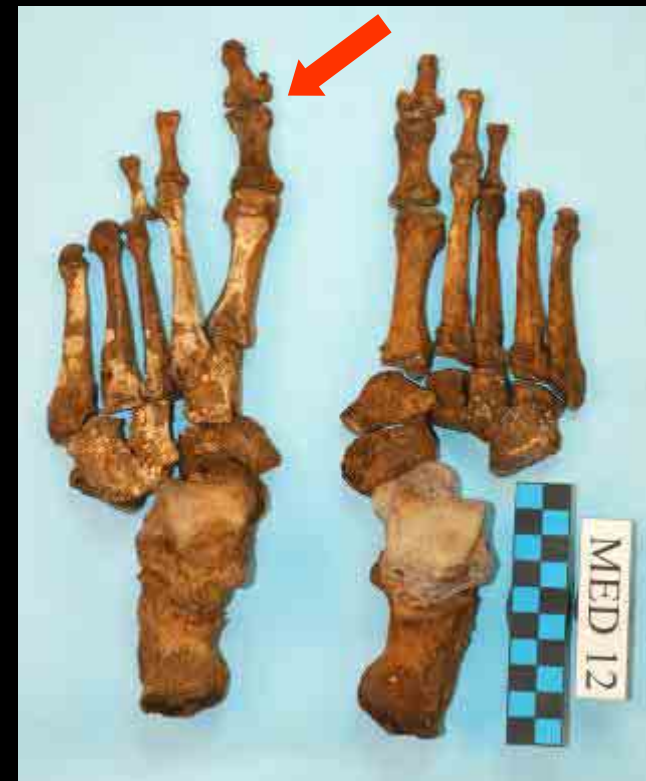
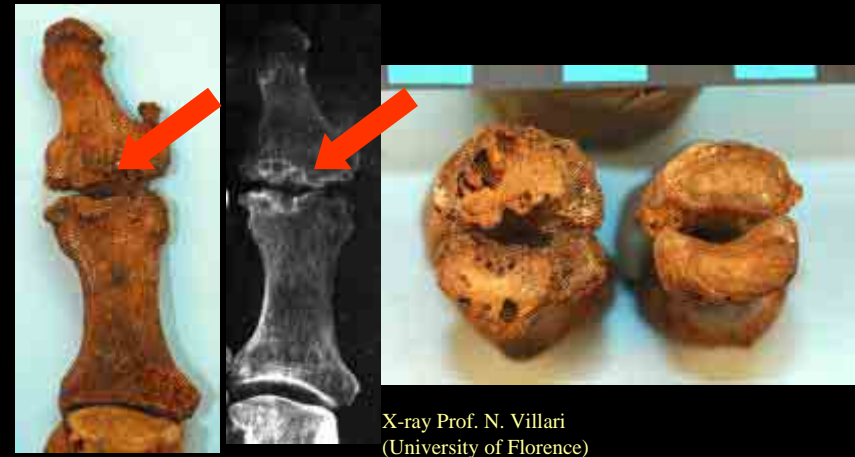
X-ray Prof. N. Villari
(University of Florence)

His left foot shows a scooped-out defect located at the peri-articular and articular surface of the interphalangeal joint of the *hallux dorsum*, with partial destruction of the sub-chondral plate (red arrows); the lesion, revealing at X-ray an evident sclerotic margin, involves both the bones of the joint and is typical of chronic gout.

Archival records contain an accurate description of a typical gout attack, as reported by the court physician Giulio Angeli: “*yesterday the gout started to pinch the big toe of the Grand Duke’s left foot and then continued to advance rapidly! Overnight the toe has become swollen, inflamed and painful*”

(2nd April 1591).



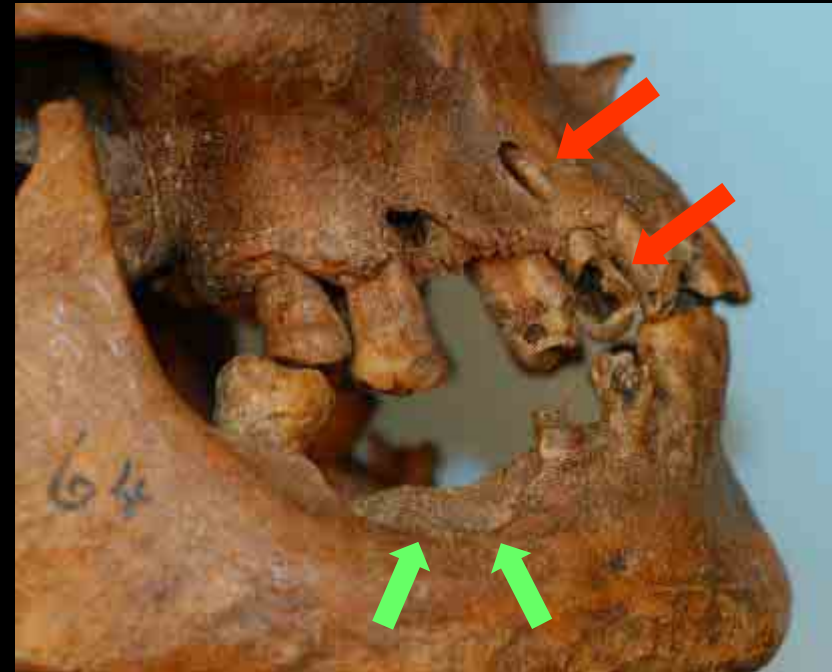
Dental Pathology

The teeth show a severe periodontal disease and several penetrating and destructive caries with peri-apical abscesses (red arrows).

At the moment of death, a large abscessual cavity, with loss of the first and second inferior right molars, was in course of recovery (green arrows).

The ambassador of the Lucca Republic Bartolomeo Cenami refers that (the Grand Duke) “*frequently, at present and in past times, suffered from toothache*”

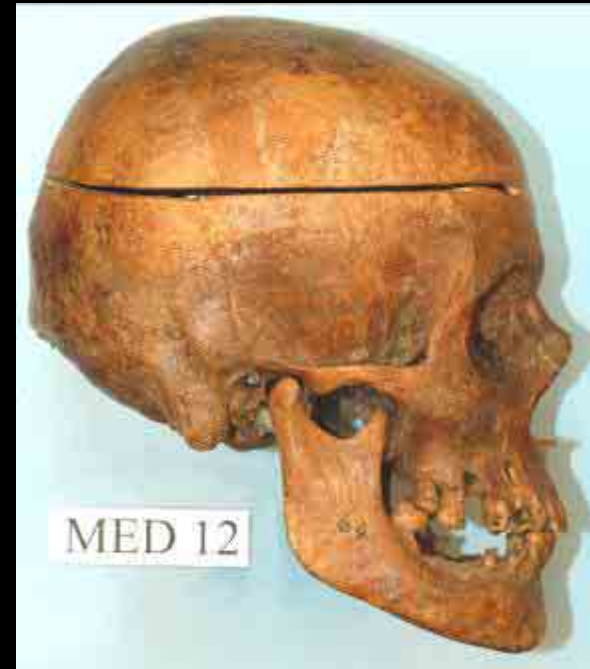
(23th June 1606)



Autopsy

At autopsy of the Grand Duke's body, the court surgeon cut the soft tissues with a very subtle blade, as proven by some horizontal and oblique thin incisions of the parietal and temporal bones (red arrows);

he then opened the skull with an accurate, horizontal cut, obtained by a bone saw.





Pulzone (c.1590), Florence, Uffizi Gallery

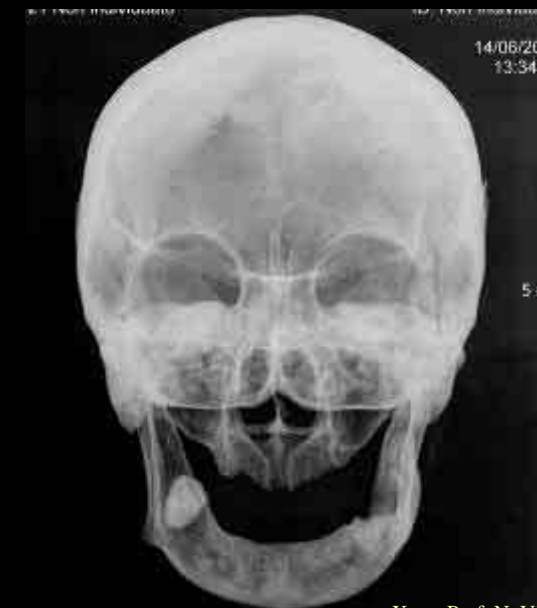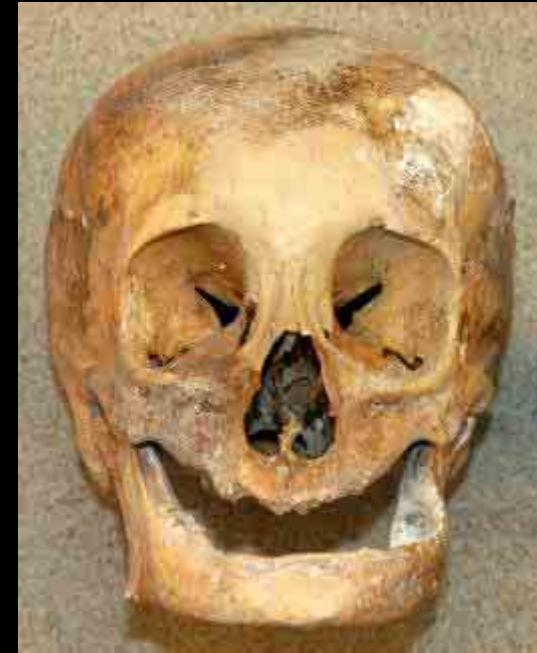**Cristina from Lorraine
(1565-1637)**

Anthropology

The skeleton of the Grand Duchess Cristina from Lorraine (1565-1636), wife of Ferdinand I, indicates a senile woman aged 60-70 years, 1.63 m tall.

Autopsy

Her sternum had also been sectioned during autopsy (yellow triangles).



X-ray Prof. N. Villari
(University of Florence)

“Clinical history”

The “clinical history” of Cristina confirms the large number of deliveries: between the ages of 25 and 39, she gave birth to as many as 9 babies and had an abortion.

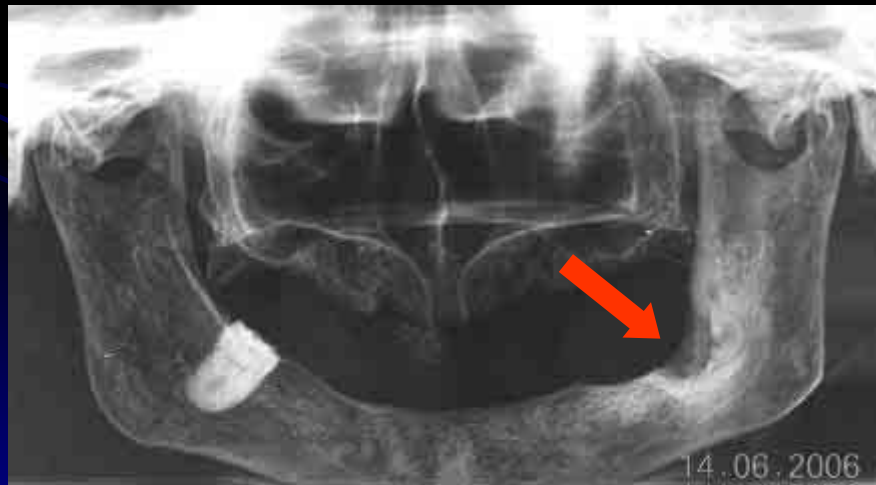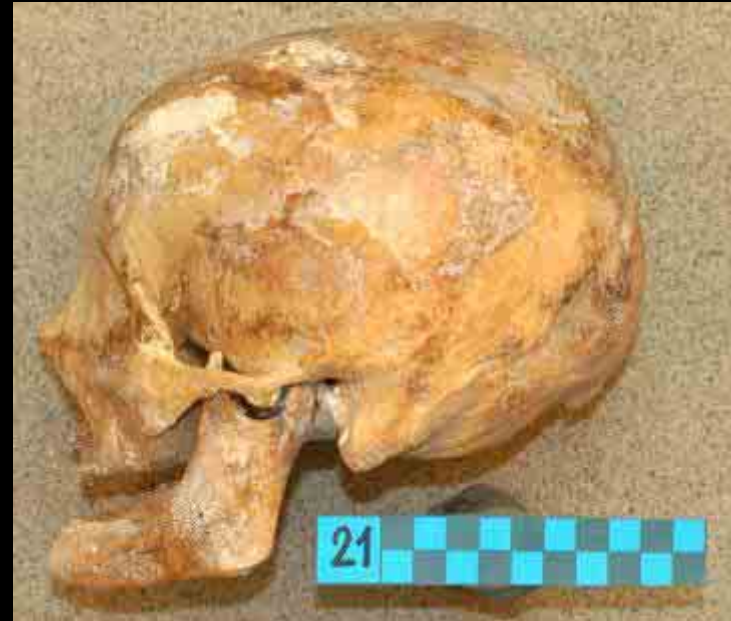After surviving several episodes of non-severe illnesses (such as acute bronchitis at the age of 28, smallpox at 29, intestinal fever at 31, malarial fevers at 36-37 and cataract problems at 69), she died of cerebral arteriosclerosis and stroke when she was 72.



Tiberio Titi (c.1615), Florence, Palazzo Pitti

Paleopathology

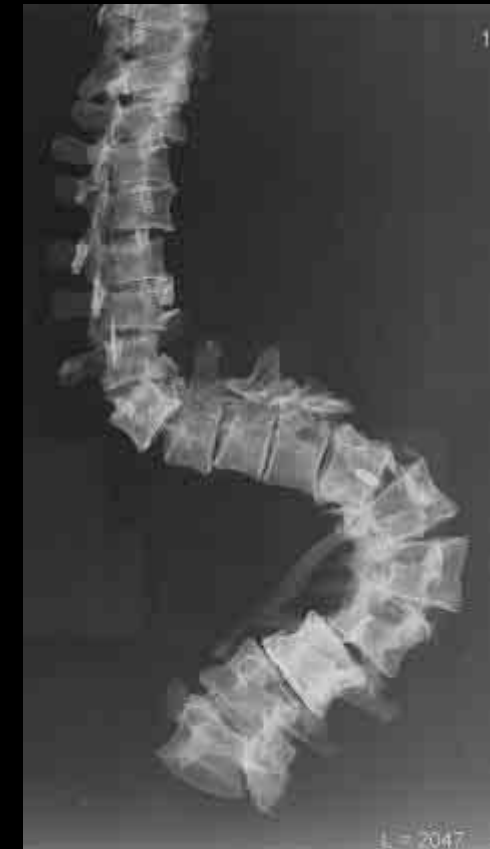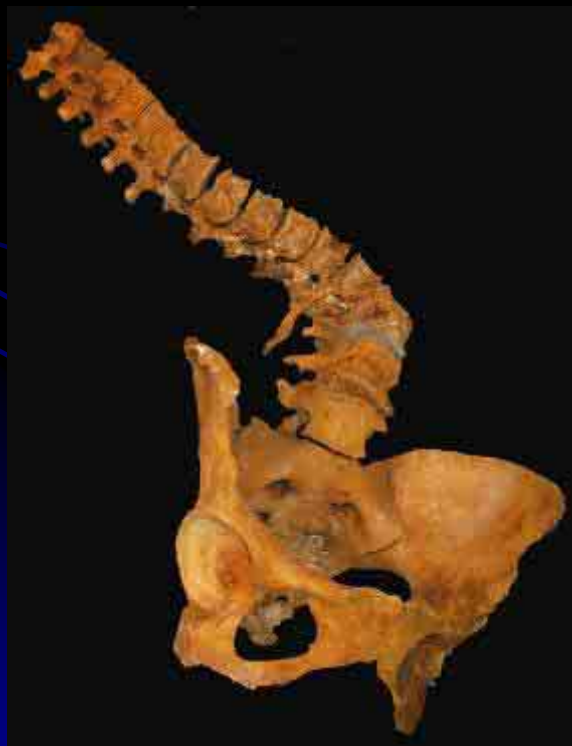The paleopathological study of Cristina's skeleton showed congenital hyperostosis (ca 1 cm) of the cranial vault, moderate vertebral and extra-vertebral arthritis, and total *intra vitam* tooth loss with a well recovered large abscessual cavity (red arrows) corresponding to the left wisdom tooth of the mandible.



X-ray Prof. N. Villari
(University of Florence)



The severe left scoliosis of the lower thoracic and lumbar column, forming an angle of about 90° , was caused by lateral wedge-shaped collapse of the bodies of the twelfth thoracic and first lumbar *vertebrae*, with partial fusion on the concavity.



X-ray Prof. N. Villari
(University of Florence)

The absence of fractures and osteoporosis suggests a static or juvenile etiology for this impressive column deformity.



Sustermans (c.1650), Florence, Palatina Gallery

**Cardinal Carlo
(1596-1666)**

Anthropology


Carlo (1595-1666), younger son of Ferdinand I, became cardinal in 1615 and dean of the Sacred College of Cardinals in 1652.

His skeleton is that of a senile man aged more than 60 years, 1.70 m tall, with severe osteoporosis, especially of the lower limbs.



Autopsy

There are two transversal cuts on the upper part of the sternum (blue arrows); the sternal extremities of the 4th, 5th, 6th and 8th right ribs, and the 5th of the left, appear completely sectioned (red arrows), probably with scissors.



“Clinical history”

We know that, at 8 years of age, he was affected by tuberculosis of the column (Pott's disease), upper thoracic or cervical.

From 24 years of age he suffered from an acute articular disorder of the feet, hands and knees, diagnosed as 'gout' by the physicians; the documents report on 18 severe attacks from the ages of 35 to 59, with worsening between 60 and 65.

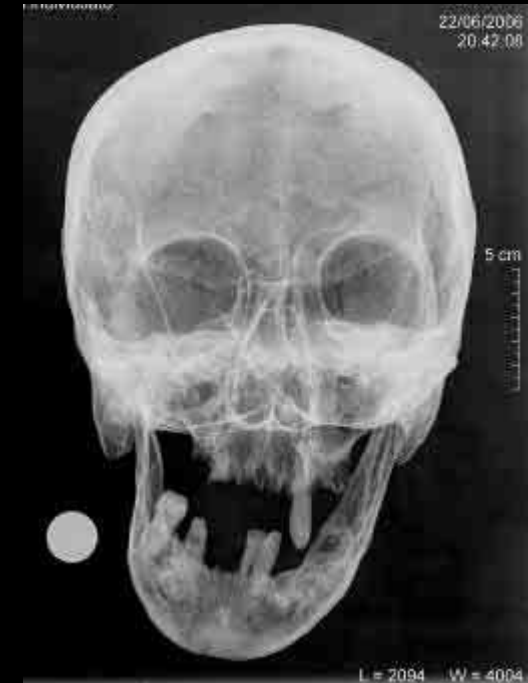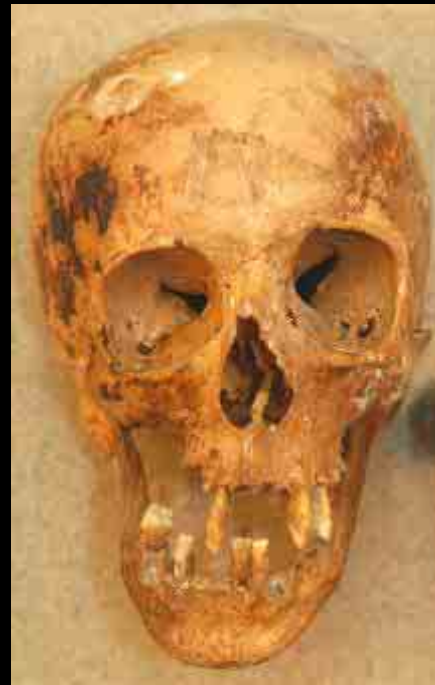From the ages of 50 to 70 he was affected by recurrent bronchitis and finally died of bronchopneumonia.



Sustermans (c.1640), Florence

Paleopathology

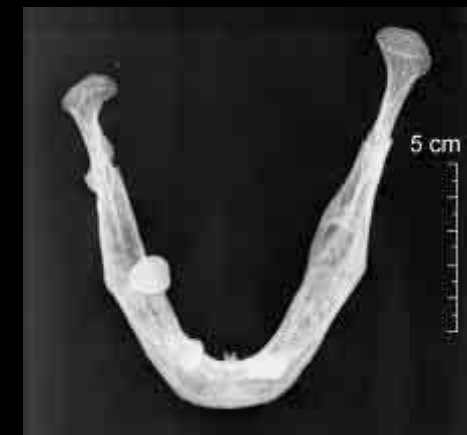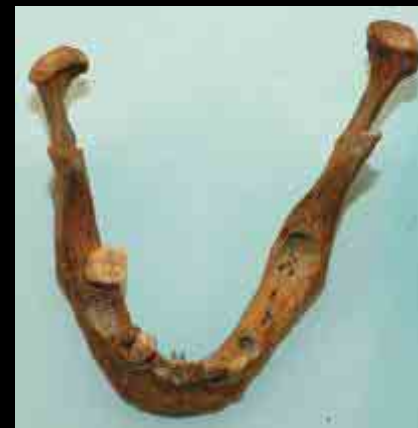The facial skeleton shows a marked hypoplasia of the right mandibular *corpus*, with right deviation of the face and probable chronic *torticollis*, as appears in a rare engraving (white arrow).



X-ray Prof. N. Villari
(University of Florence)



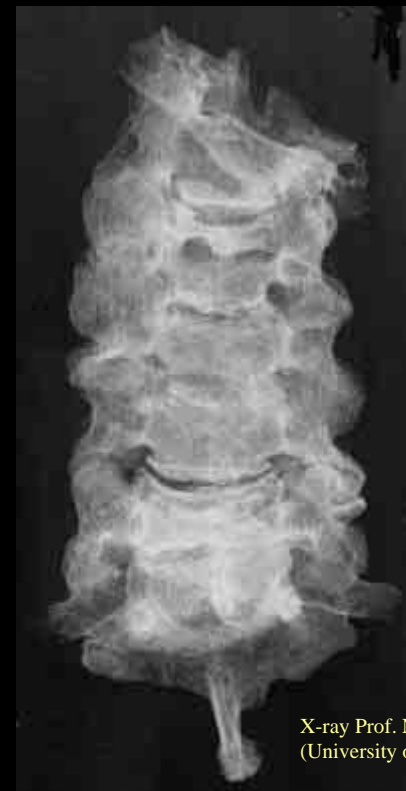Haelvegh, engraving



X-ray Prof. N. Villari
(University of Florence)

There is congenital fusion of the *atlas* with the occipital bone. The articular facets, pillars and posterior bodies of the 1st-5th cervical *vertebrae* are also fused, with narrow disc spaces, forming a C1-C5 block.

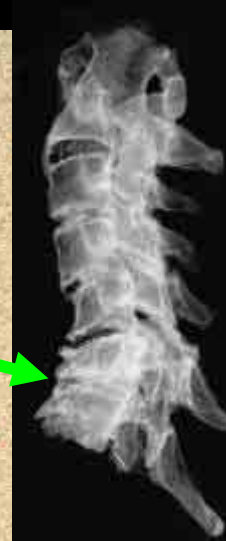This cervical anomaly, known as Klippel-Feil's syndrome, is frequently associated with *torticollis*.



X-ray Prof. N. Villari
(University of Florence)

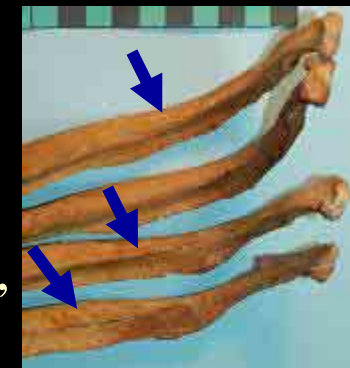
A second block, involving the vertebral bodies with wedge-shaped collapse, fusion, and formation of an angular kyphosis (green arrows), is at the level of C6-C7.

X-ray confirms body fusion (green arrows).



X-ray Prof. N. Villari
(University of Florence)

There is also diffused periostitis of the internal surface of the ribs (blue arrows), typical of tuberculosis.



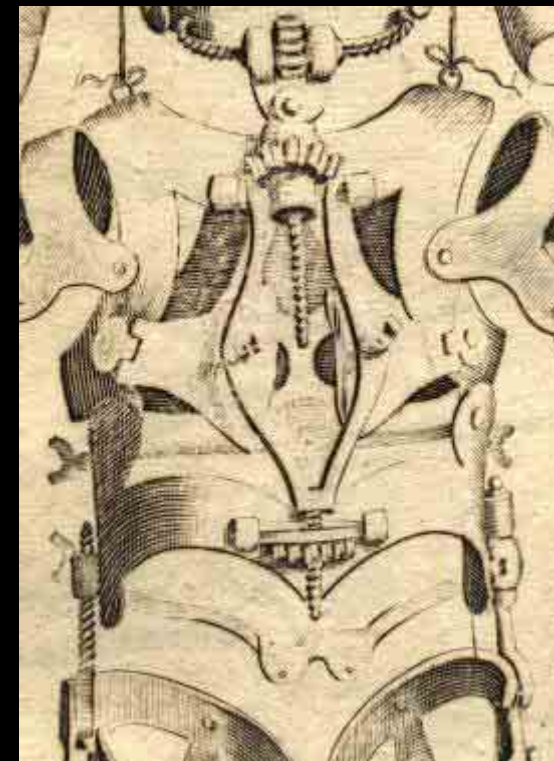These are the results of the cervical spine tuberculosis (Pott's disease), characterized by neck *fistula* and *gibbus*, well described in the archival records, at 8 years of age.

Ferdinand I called one of the most famous physicians of that period, Girolamo di Fabrizio d'Acquapendente, professor of medicine at the University of Padua and pioneer in orthopedics, to cure his son.



The doctor applied to Carlo, who was starting to become hunchbacked:

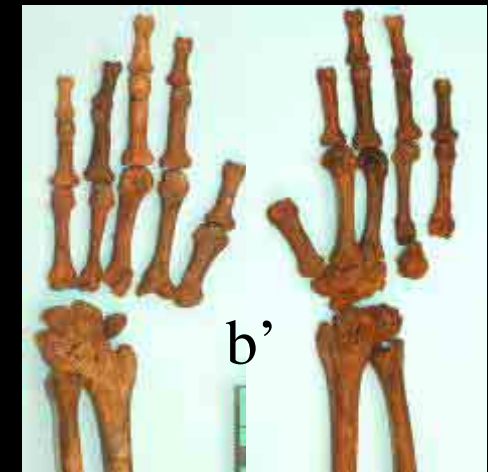
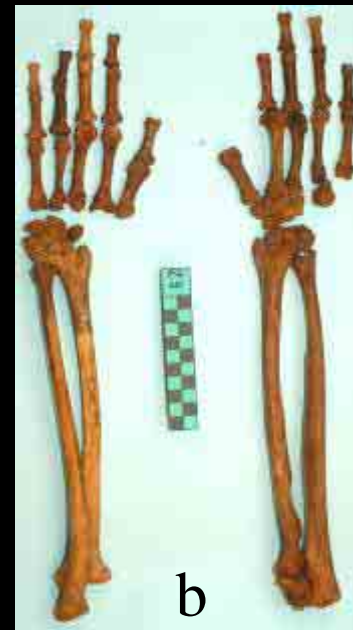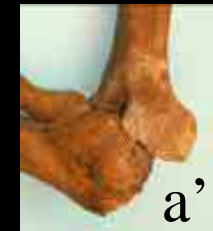“... an iron tool pushing and bringing the vertebrae in opposite position... to this purpose I have prepared a hauberk, or light body armour in iron, with particular screws pushing the vertebrae which are out of place, gradually restoring them to their original position.”



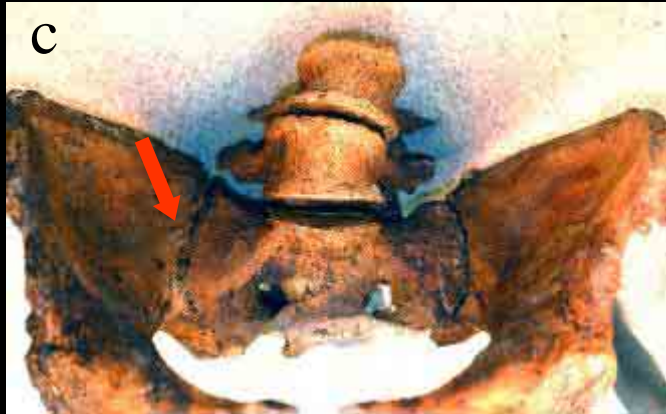Surgical works, published in Padua in 1658 by G. Cadorino, p. 174

The post-cranial skeleton shows an ankylosing disease, symmetrical and extremely severe, of the great and small articulations, characterized by:

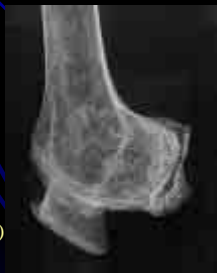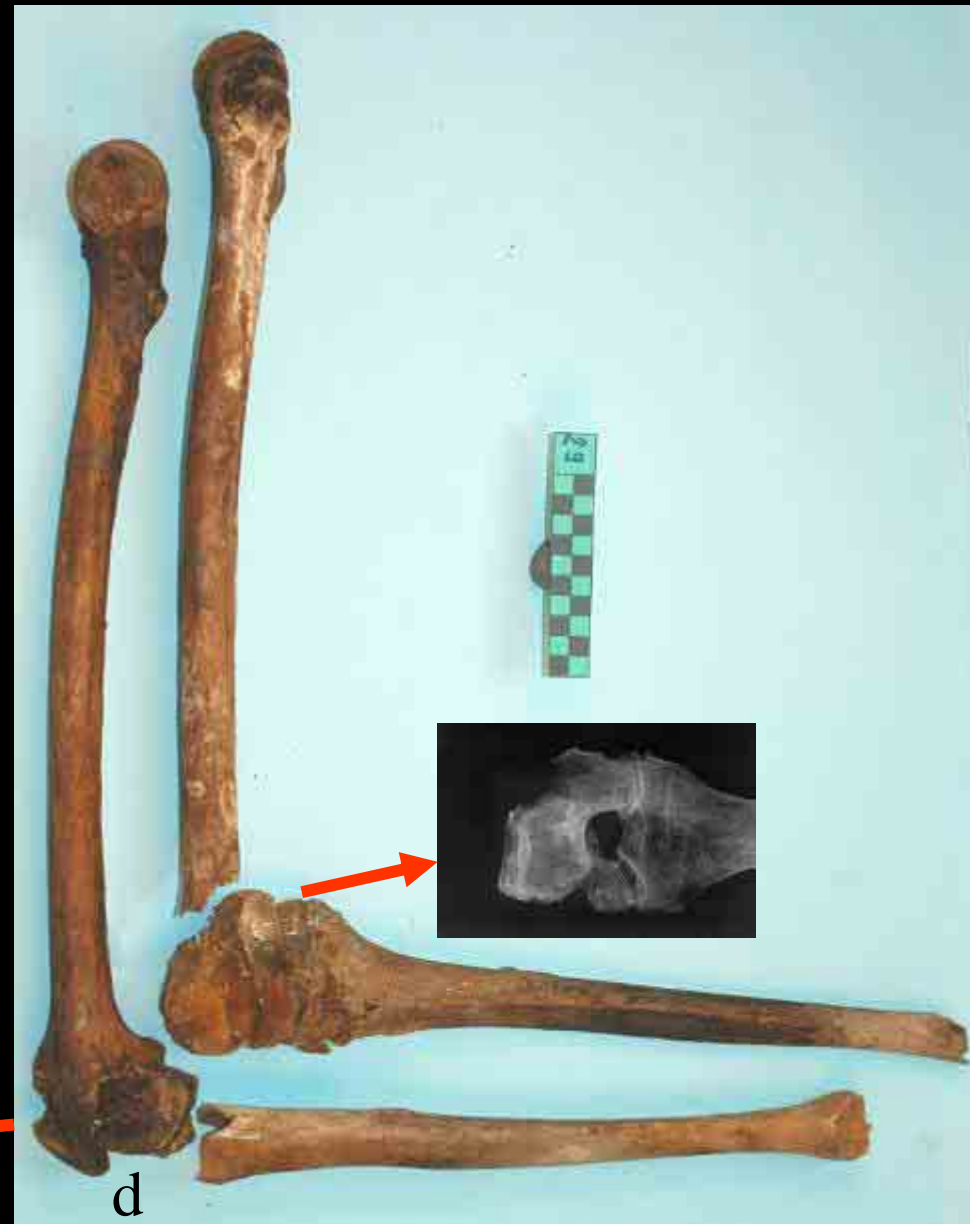
- Fusion of the left elbow (in flexion at 55°) (a, a');
- Bilateral fusion of wrists, carpal bones, and some fingers (b, b');



- Fusion of the right sacroiliac joint (c)
(red arrow)

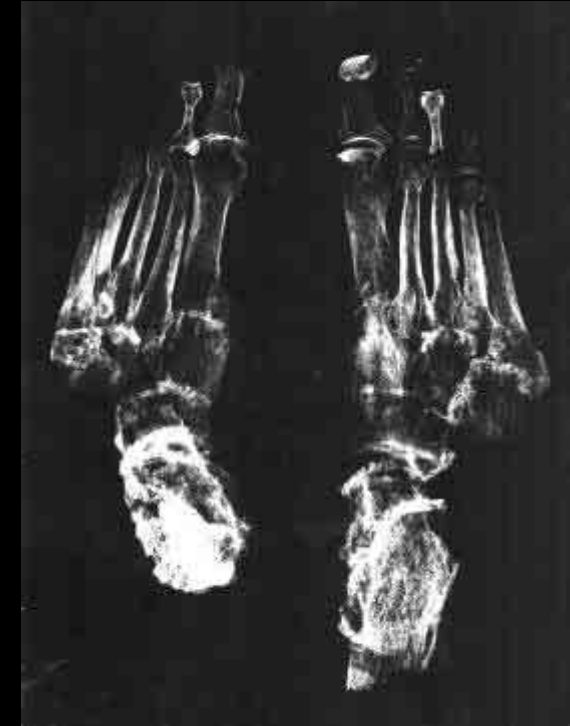
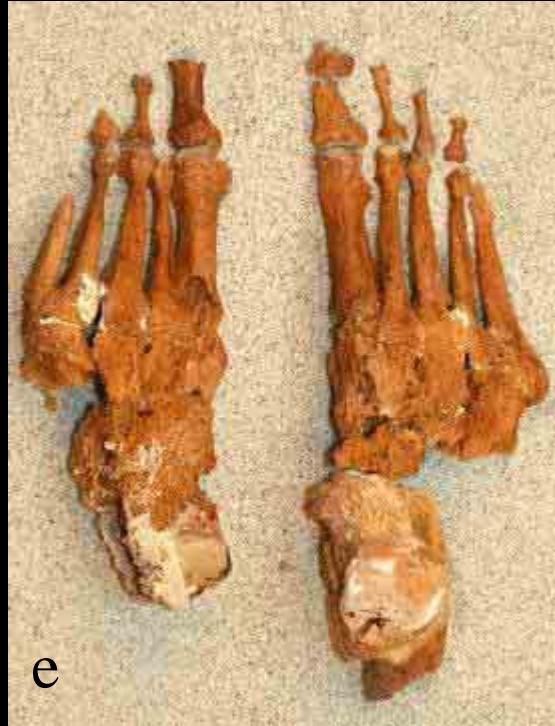

- Fusion of knees and *rotulae*
(in flexion at 90°) (d)



X-ray Prof. N. Villari
(University of Florence)

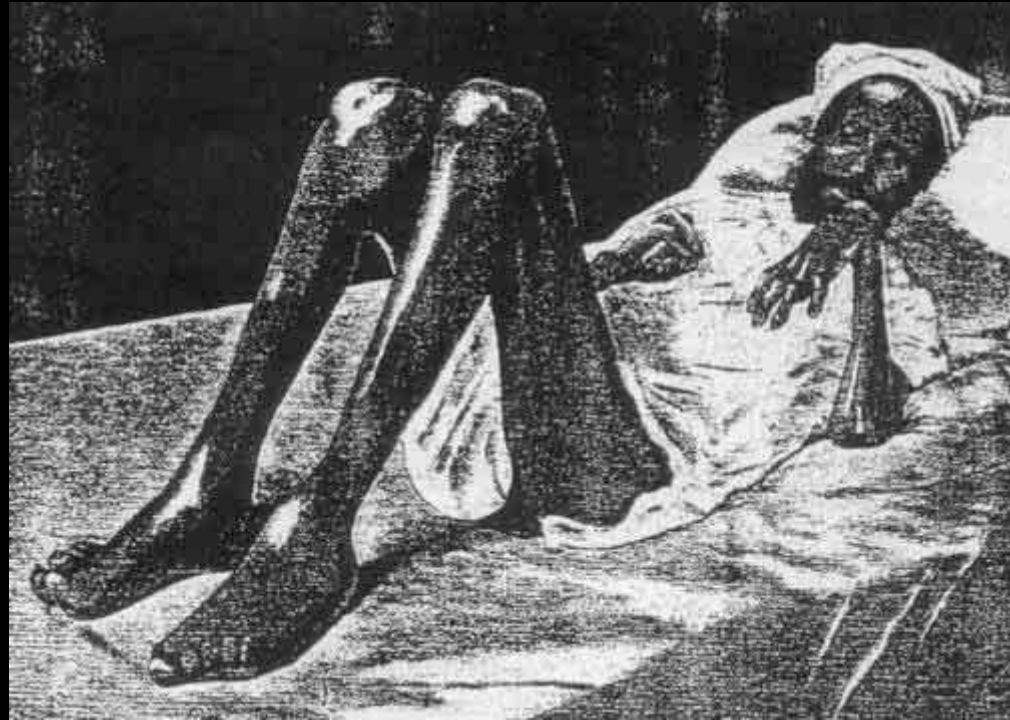- Fusion of tarsal and metatarsal bones (e)



X-ray Prof. N. Villari
(University of Florence)

This data, together with the very severe osteoporosis, in particular of the lower limbs, demonstrates the cardinal's total disability, in the last years of life, as reported by the archival documents. Indeed, from 1658 (at the age of 63), the cardinal was no longer able to sign any letters or documents. In a letter to a nephew he writes: “Y(our) H(ighness) *please excuse me for not being able to sign in my own hand (writing), because my hand does not function*”

(4 December 1658)



Possible terminal “clinical picture” of the cardinal
(Pasero G, Marson P. The antiquity of psoriatic arthritis.
Clin. Exp. Rheumat. 2006; 24: 352)

The “clinical” and pathological picture clearly shows severe, symmetrical polyarthritis. At present we can only speculate on a case of rheumatoid or psoriatic arthritis. The molecular study is in course.



Florentine painter (1614), Florence, Uffizi Gallery

Prince Francesco (1594-1614)

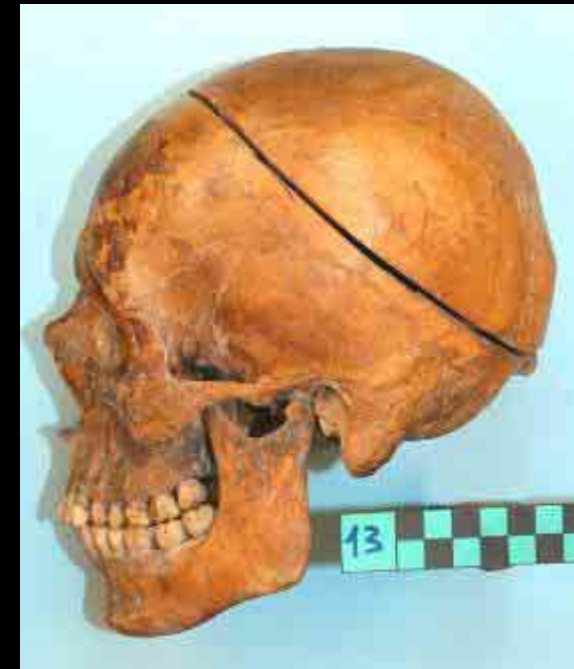Prince Francesco (1594-1614) was a young son of the Grand Duke Ferdinand I. He died at 20 years of age of an acute intestinal disease, probably abdominal typhus.

The anthropological study of the skeleton reveals a young male of about 18-23 years, 1.80 m tall, with strong, but not particularly developed muscular insertions.

Autopsy

At autopsy, the court surgeon opened the skull with an accurate, oblique cut, obtained with a bone saw.

The sternal *manubrium* also reveals a deep, transverse incision (red arrow).



From the archival documents we know that Francesco entered the military career when he was 15, and in 1613, at only 19 years of age, he led the Tuscan army against the Duke of Savoy.

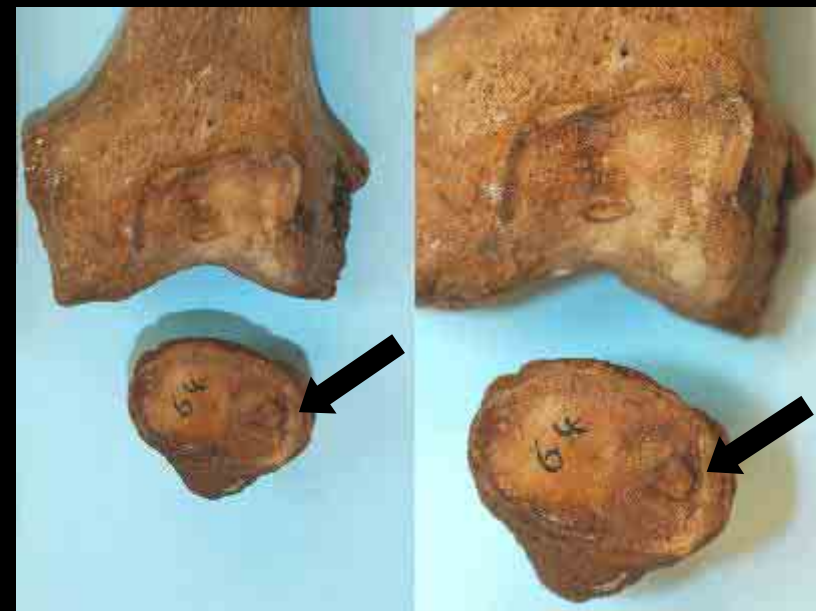


Florentine painter (1614), Florence, Uffizi Gallery

The paleopathological study of the skeleton shows, in addition to a slight arthritis of the great joints (very rare in young individuals) two interesting and probably associated lesions: the presence of a right *os acromiale* (red arrow) and *osteocondritis dissecans* (black arrows) of the left knee.

Os acromiale consists in the non-fusion of the *acromion* process of the *scapula*, a very rare trait (0.5%) in contemporary populations. Instead, this is very frequent in two skeletal samples of ancient English archers of 15th and 16th centuries.

Osteochondritis dissecans is a disorder that develops in response to repetitive traumas, especially in young, physically very active individuals.



In the case of prince Francesco these two lesions can be associated with the strenuous exercise in the use of weapons - in particular of the long bow - by a not very well trained individual.

Indeed, many long bows are present in the Medici armory of that time.



Armor of Francesco I (1570-1575)
Florence, Bargello Museum



Helmet of the Prince Mattias
(c. 1620-1630)
Florence, Bargello Museum




Large curve bow , or Syrian (16th century)
Florence, Bargello Museum

Children




Tiberio Titi (1597), Florence,
Uffizi Gallery



A preliminary study of the skeletal remains of 8 young individuals between 0 and 5 years of age allowed us to diagnose three cases of rickets (a) and three cases of poroctic hyperostosis (b), of which two were quite severe.

It is very likely that rickets was caused by the scarce exposure to light of the children in the environment of the Renaissance courts, while poroctic hyperostosis was determined by prolonged nursing of the babies.



The anthropological study of individual n. 39 from the crypt of the Grand Duke Gian Gastone, nicknamed “the child with the red jacket”, revealed a little boy of about 5 years, with a stature of ca 1.15 m.

The child is almost certainly don Filippino, son of the Grand Duke Francesco I, who died in 1582 at the age of 5.

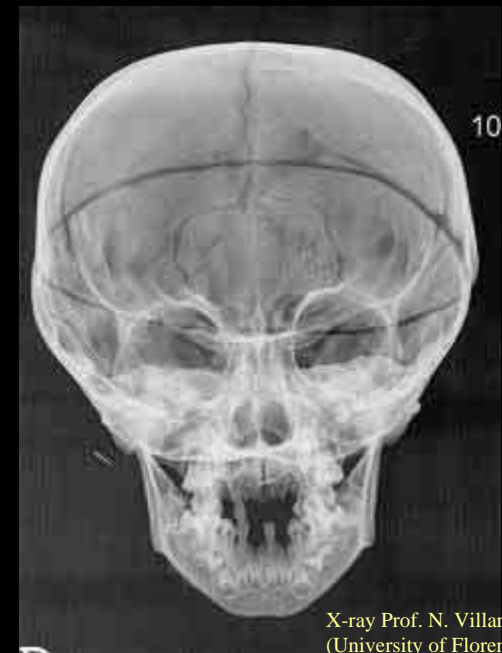
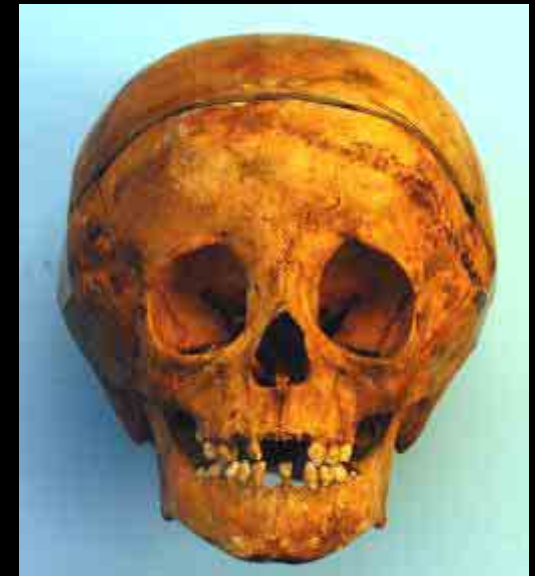
The paleopathological study shows evident hydrocephaly and slight rickets, with curvature of the left *tibia* and *fibula*.

A portrait of don Filippino, painted in the same year of death (1582), shows a picture of non-severe hydrocephaly, with low implant of the orbits and auricles and evident expansion of the cranial vault.



Allori copy (1582?)
Florence, Poggio Imperiale Villa



X-ray Prof. N. Villari
(University of Florence)

The archival documents contain the autopsy report of don Filippino, which provides an accurate description of a typical hydrocephalus:

“On 29th March Filippo, great Prince of Florence, died... he was buried in (the church of) san Lorenzo. The doctors who had cured him – both physicians and surgeons – cut his head removing the cranial vault as if it were a bowl and found, underneath the first membrane of the brain, (the equivalent of) almost a glass of water, so that they all thought that this had been the real cause of his death”

Lapini, Florentine Diary, 1589

...”(The doctors) opened the (body of the) Prince and found his head full of water”

Letter of the Grand Duke Francis I to his brother, the Cardinal Ferdinand (7th April 1589)



CONGENITAL	Klippel-Feil syndrome, chronic <i>torticollis</i> , cranial hyperostosis, <i>amelogenesis imperfecta</i> , hydrocephaly
ARTICULAR	degenerative arthritis, DISH, polyarthritis
SPINAL	scoliosis, pelvis deformity
METABOLIC	porothic hyperostosis, rickets, gout, osteoporosis
INFECTIOUS	tuberculosis
OCCUPATIONAL	<i>os acromiale</i> , <i>osteocondritis dissecans</i>
DENTAL	periodontal disease, caries, abscesses
MEDICI PATHOLOGIES (September 2006)	

I have reported here only the first results of the examinations of 20 of the 49 Medici tombs in the Basilica, including those of 8 children. The laboratory studies are still in progress.

An additional 29 burials, mostly intact, will be explored in the next two years, and we are convinced that we will obtain other important results.

We trust that this multidisciplinary study of the Medici funerary depositions and bodies will increase considerably our knowledge of the diseases and life style of the members of the Medici family, so important for Italian Renaissance.

Paleopathology rewrites history!



Cosimol
(1519-1574)



Gian Gastone
(1671-1737)

Institutions involved



University of Pisa

Superintendence of Florentine Museums

University of Florence

Opificio delle Pietre Dure

Opera Mediceo-Laurenziana

University of Long Island

University of Minnesota

MGM Biotechnology, Pisa